

Shotgun Injury to the Arm: A Staged Protocol for Upper Limb Salvage

*Darabos Nikica, MD, PhD**; *Cesarec Marijan, MD†*; *Grgurovic Denis, MD‡*;
Rutic Zeljko, MD‡; *Darabos Anela, MD‡*; *Kenneth Egol, MD, PhD§*

ABSTRACT Low-energy shotgun fractures involving the arm are complex injuries. Previously published reports have emphasized various problems associated with these injuries. This case report describes a low-energy shotgun wound managed by a staged treatment protocol involving: (1) a spanning external fixator and immediate soft tissue management, followed by (2) osteosynthesis and autogenous bone grafting and (3) epineural suturing of injured radial nerve, with a successful outcome. Although adequate debridement of the fracture and soft tissue wound is the key to open fracture management, some difference of opinion exists with regard to the timing of bone reconstruction and grafting. In severe type III open fractures, or in wounds that are marginal, it may be best to delay cancellous bone grafting until soft tissue has stabilized following acute trauma when the risk of infection has been minimized. If early coverage of vital structures is not possible, local or remote flap coverage may be necessary.

INTRODUCTION

Shotgun wound fractures in general fall within two categories: low-energy (<200 ft/sec) shotgun wounds, which are common in civilian criminal activity and high-energy ballistic (>200 ft/sec) injuries, which are associated with missiles and other weapons of war. Despite surgeons' best efforts at limb salvage, these injuries may result in extremity amputation. A number of strategies for the management of complex bone and soft tissue injuries associated with severe traumas have been reported.¹⁻⁸

This case report describes a low-energy shotgun wound managed by a staged treatment protocol involving a spanning external fixator and soft tissue management, followed by osteosynthesis and acute bone grafting with a successful outcome.

Case Report

A 60-year-old, left hand-dominant male received a low-energy shotgun wound of the left arm while serving in the military. The weapon was a Zastava M75 16 gauge shotgun, fired from a close range, at a distance of about 20 cm. The wound was highly contaminated with an approximately 10-cm zone of injury and resultant bone and soft tissue loss (Fig. 1).

*University Clinic for Traumatology, Medical School, University of Zagreb, Draskoviceva 19, 10000 Zagreb, Croatia.

†Department of Traumatology, Varazdin General Hospital, I. Mestrovica 1, 42000 Varazdin, Croatia.

‡The Scientific Unit, Varazdin General Hospital, I. Mestrovica 1, 42000 Varazdin, Croatia.

§Department of Orthopedic Surgery, NYU Hospital for Joint Diseases, 301 E. 17th Street, New York, NY 10016.

Previous presentation: Osteosynthesis and Trauma Care (OTC) Foundation meeting, St. Petersburg, Russia, 2007; OTC fellowship, New York, 2008.

Investigation with the human subject reported in the article was performed with informed consent and following all the guidelines for investigation with human subjects required by the institution(s) with which all the authors are affiliated.

The patient received first generation cephalosporin and tetanus prophylaxis in the emergency department and was indicated for surgical intervention. Systolic blood pressure was lower than 90 mmHg, but the hand was warm and well perfused. There were no hard signs of brachial artery injury, but the patient was noted to have diminished distal pulses. There was no clinical evidence or laboratory evidence of disseminated intravascular coagulation (DIC). There was a lesion of the radial nerve.

Following a complete trauma work up, the patient was brought to the operating room where he underwent his first in a series of planned operative interventions. Upon further exploration, the patient was noted to have the following neural injuries: traumatic laceration of cutaneous branches of the axillary nerve, 1-cm-long defect of the radial nerve, absence of the posterior cutaneous nerve of the arm and motor branches to the long, lateral, and medial triceps muscle. The bone injury was classified as a comminuted fracture of the proximal third of humerus. There were many free devitalized bone fragments, which were debrided. There was approximately 10 cm of humeral bone defect following debridement, which was typed as a IIIB according to Gustillo's Classification.^{9,10} The soft tissue loss included the following: the lateral head of triceps brachii muscle, almost all of biceps brachii, brachialis, and coracobrachialis muscles with their concomitant arterovenous supply, covering soft tissue and skin of anterior and posterior parts of the upper arm. The status of deep brachial vessels and of the ulnar and median nerves was confirmed intact. The wound was further classified as E30, X30, C1, F2, V0, M2 according to the Red Cross wound classification.^{11,12} Mangled extremity severity score (MESS) was 7.¹³

Initial operative treatment included: (1) irrigation and initial radical debridement of the wound, (2) bone stabilization with an external fixator adjusted to shorten the upper arm and thereby close the gap/prevent tension on future neural anastomosis, and (3) epineural suturing of the radial nerve. Acute

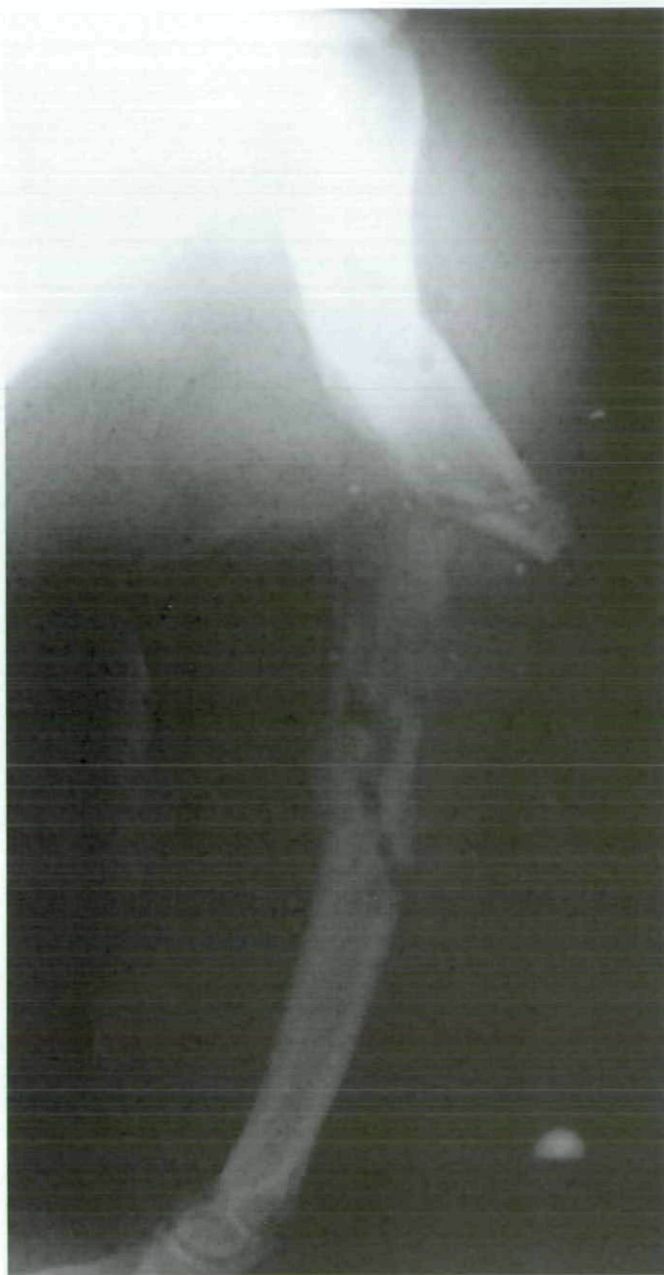

FIGURE 1. X-Ray after admission.

bone grafting of the defect was deferred due to the risk of wound infection. The wound was packed open to be changed daily with normal saline wet to dry dressings (Fig. 2).

The patient received a repeated treatment of irrigation and debridement on hospital days 2, 4, and 6 post trauma. On day 7 post trauma with no signs of infection, definitive bone fixation was performed, which consisted of the removal of the external fixator and intramedullary unreamed nailing. In addition, corticocancellous bone autografting was performed along with definitive wound coverage using a muscle flap of long and medial heads of triceps brachii and STSG (Figs. 3 and 4).

Three months following the injury there was no sign of infection, but the patient had not shown any radiographic progression




FIGURE 2. Shotgun injury of arm after first operation: anterior aspect.

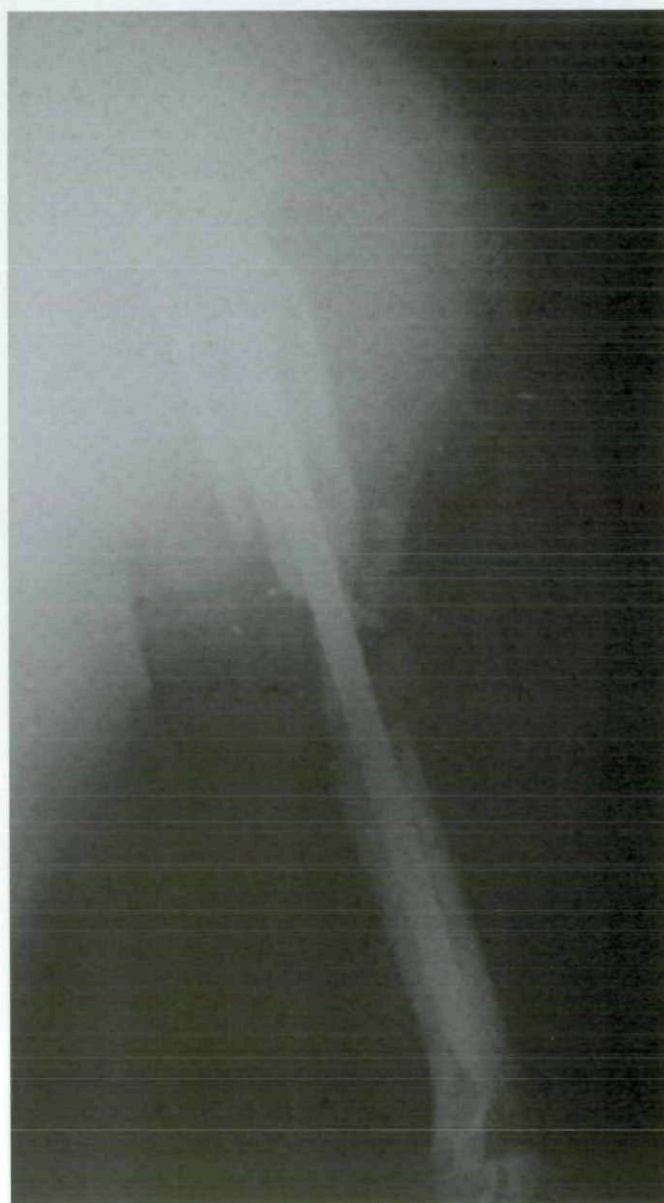

FIGURE 3. X-Ray after second operation.

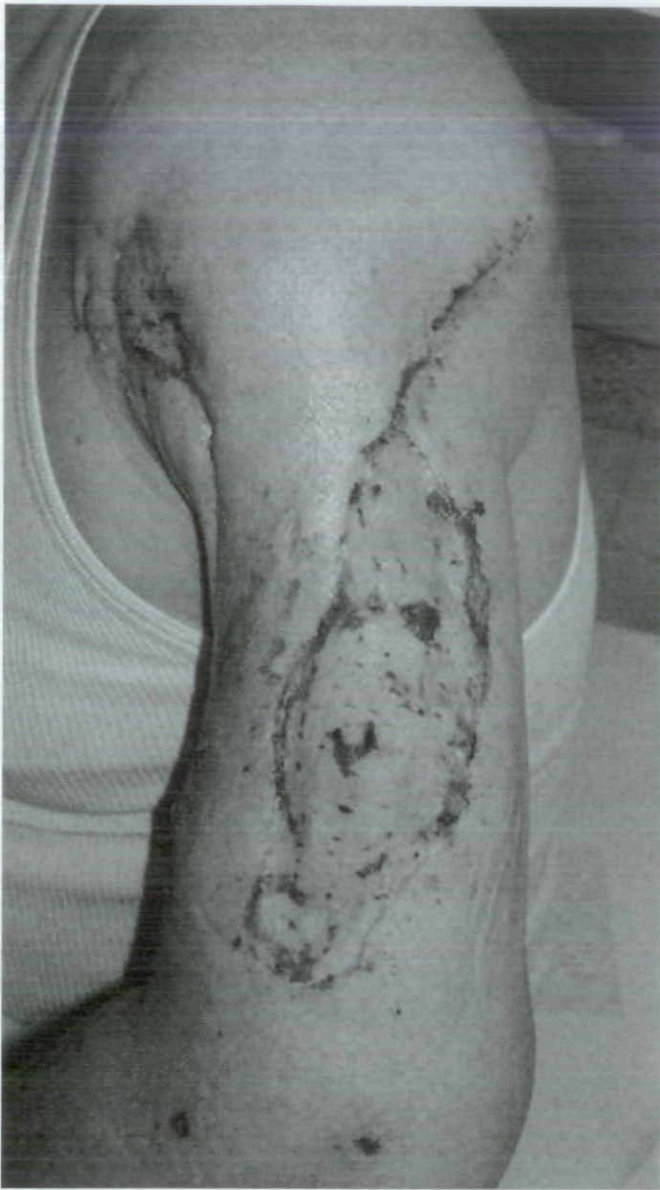

FIGURE 4. Shotgun injury after second operation: lateral aspect.

toward bone union and was indicated for further surgery. The patient underwent a third operation, which included another autogenous bone graft to the bone defect site.

At 6 months post-trauma radiographs showed signs of bone union. The circulation to the hand was maintained and there were no signs of infection. The neurologic status improved with almost full radial motor reinnervation. The shoulder had limited abduction for one-half of movement, elevation, and external rotation for one-third of movements and terminal reduction of internal rotation; elbow extension and rotations were limited in terminal movements and flexion for one-third of movement, whereas there was no limitation in wrist movements (according to the opposite site). The range of shoulder, elbow, and wrist motions improved and became functional (Figs. 5, 6, and 7). There were persistent paresthesias in the

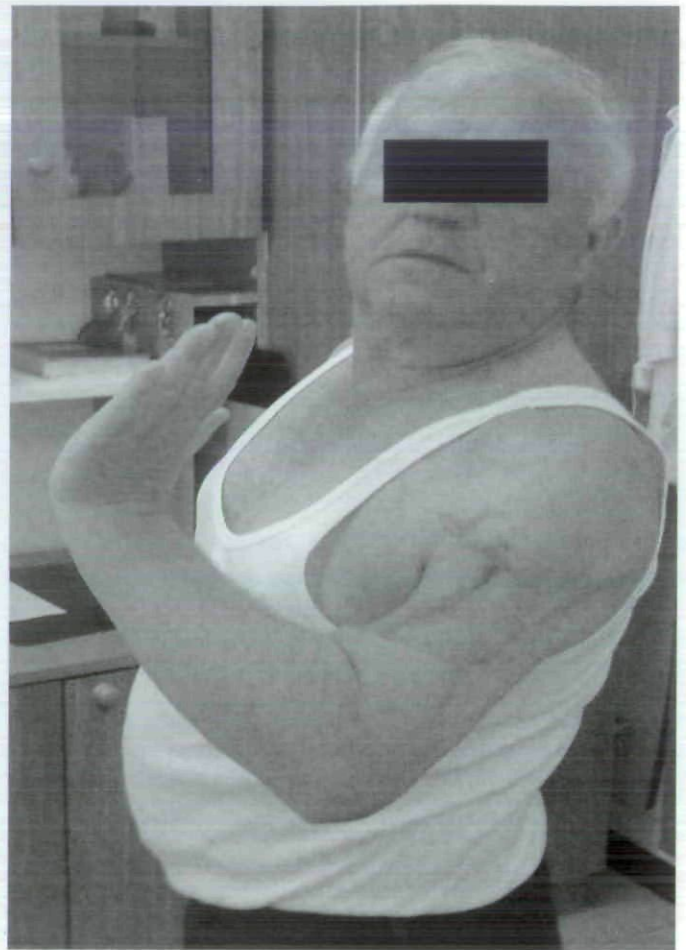

FIGURE 5. Functional status 6 months post-trauma A.

distribution of the superficial radial nerve in the hand and fingers. The results of electromyoneurography revealed a diminution of motor units in the forearm caused by the loss of muscular masses. One year post injury, the radiographs showed a qualitative bone union (Fig. 8). The clinical status of the patient was unchanged and he returned to his duty.

DISCUSSION

Low-energy shotgun fractures involving the arm are complex injuries. Previously published reports have emphasized various problems associated with these injuries.¹⁻⁸

This case report presents a staged management for the treatment of a complex upper extremity shotgun wound involving bone, muscle, and nerve tissue. Despite a MESS score of 7 points the patient would not consider the possibility of amputation, and limb salvage was undertaken. The success in this case is another example of the problem associated with assigning risk for amputation, rather than treating each situation individually. For the surgeon, many of the dilemmas concerning if, when, and where to amputate, as well as other issues related to this treatment have diminished by utilizing modern supportive measures.¹⁴

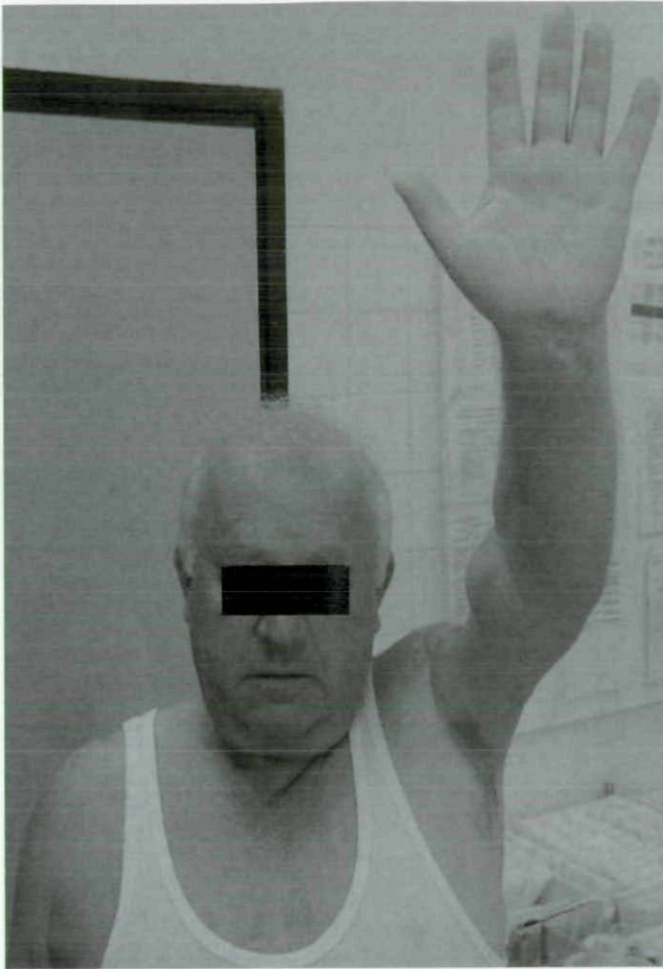


FIGURE 6. Functional status 6 months post-trauma B.




FIGURE 7. Functional status 6 months post-trauma C.

Bullets fired from low-energy weapons tend to result in minimal tissue cavitations as compared to higher-energy weapons. Stable, extra-articular fracture patterns seen with these injuries may require only local irrigation and debridement

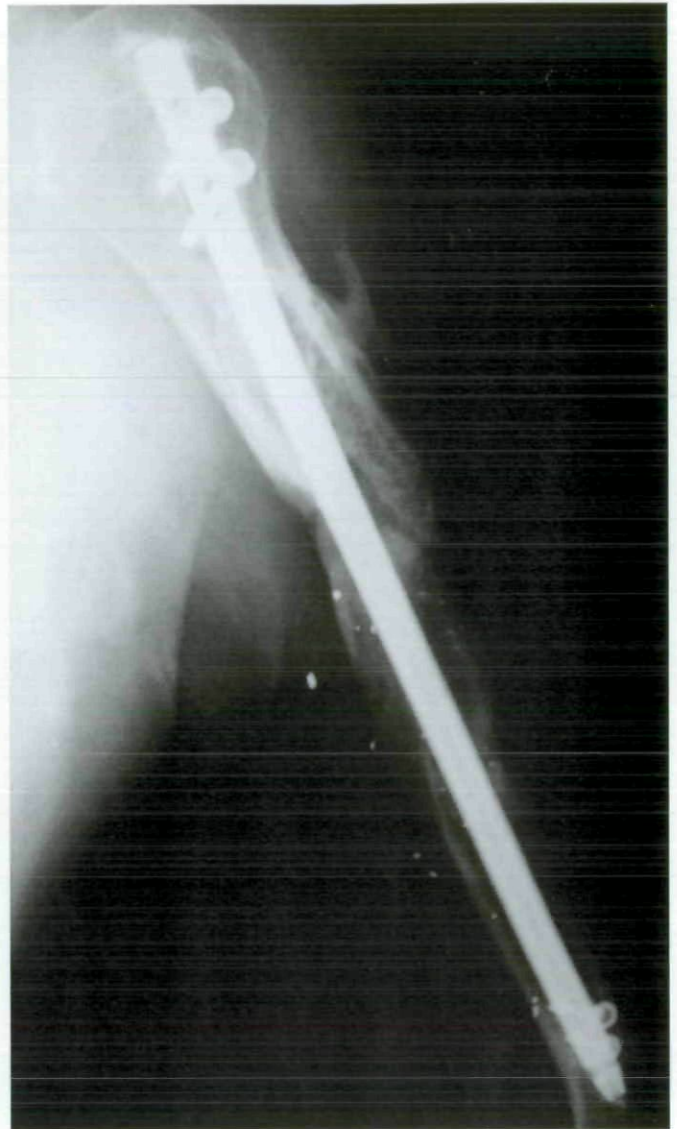


FIGURE 8. X-Ray 1 year post trauma.

with splinting or bracing vs. internal fixation at the surgeon's discretion. However, all patients who sustain these injuries should receive tetanus prophylaxis and short-term intravenous antibiotics.^{8,15,16}

Elstrom et al.¹⁷ suggest that external fixation alone is adequate for undisplaced fractures associated with shotgun wounds. As to displaced fractures, these authors reported that delayed (7 to 14 days) primary internal fixation following the initial phase of wound healing had proven benign, and led to results that were superior to those obtained from other forms of treatment.¹⁷⁻¹⁹

Soft tissue management of these injuries is controversial.^{20,21} The timing of definitive closure depends on many factors including the amount of initial contamination, the availability of local soft tissue and of technical expertise. Failure to perform an adequate, wide surgical debridement is the main cause of associated post injury wound infection

and abscess formation.²² Whether a wound has been appropriately debrided requires substantial experience and proper judgment. Because of the difficulty in determining viability of the surrounding soft tissue envelope, surgeons often choose to perform repeat irrigation and debridement until all tissue viability within the zone of injury is declared as it was done in this case.

The routine use of antibiotic bead pouches first and more recently, negative pressure vacuum assisted closure may have made acute closure of the wound less necessary than in the past. Delayed wound closure at the time of repeated debridement is safe, effective, and involves less risk.²³ Vacuum-assisted closure appears to be a viable adjunct to the treatment of open high-energy injuries. This device, however, does not replace the need for formal debridement of necrotic tissue, but it may avoid the need for a free tissue transfer in some patients with large traumatic wounds.²⁴ The case for a delayed wound closure is made on the basis of several parameters that include: surgical team availability, the condition of the patient, and adequate informed consent.²⁵ Delayed wound closure is the rule, whereas emergency free tissue transfer is an exception in major trauma centers around the world.²⁶

More rapid closure of these wounds is a possibility nowadays. Modern techniques of wound debridement and immediate administration of antibiotics have made immediate wound closure predictably safer.²⁷ European surgeons have advocated an early "fix and flap" practice that has yielded good results, with lower rates of infection than those that occurred with standard staged soft-tissue reconstruction procedures.²⁸ Furthermore, a staged wound closure requires a second surgery, which is costly and may often be avoided.²⁹ Complications are more likely to occur when there is a delay between the time of injury and the initial treatment. The development of infection in minor shotgun wound injuries is an unusual occurrence when these injuries are limited to the soft tissue structures. Additionally, wound debridement and antibiotics are often unnecessary in minor uncomplicated shotgun wounds, but may be beneficial in patients who have sustained multiple injuries, gross wound contamination, significant tissue devitalization, large wounds, or delay in treatment.^{25,30}

Deitch et al.³¹ conclude that the major cause of a prolonged hospital stay in these patients is the presence of a major soft tissue injury, whereas the presence or absence of a neural injury is the most important determinate of whether an extremity would be functional. It appears that neither skeletal nor vascular injuries result in long-term extremity disability following such injuries.³¹ They recommend an aggressive operative approach toward early wound closure to decrease hospitalization time. Furthermore, these authors also believe that the presence or absence of neurologic injury in patients is an important component of their long-term management.³¹

One study has shown that liberal use of arteriography and fasciotomy, early fracture stabilization, repair of all significant vascular injuries, and early coverage of vital structures all contribute to a successful outcome in patients with extrem-

ity gunshot wounds.²¹ In our case we chose not to perform arteriography despite the proximity of the blast to the brachial artery and the presence of distal diminished pulses because of the persistence of a well-perfused hand and the absence of vascular hard signs.

The initial indication for external fixation in the treatment of this fracture was the large, soft tissue wound associated with the missile, including that requiring neurovascular repair. Theoretically, fixator causes limited damage to the remaining blood supply of the bone and does not interfere with neurovascular repair or with postoperative wound care. Rates of deep infection vary dramatically and are probably related to the degree of underlying soft tissue injury rather than to the implant. Functional results following external fixation for select fractures, though, appear to be as good as those of intramedullary or plate fixation. The incidence of nonunion in cases of externally fixed upper extremity fractures varies from 5 to 62%.^{32,33} Early autogenous iliac crest bone grafting may be indicated to reduce the rate of nonunion in patients with extensive soft tissue injury, bone loss, or no evidence of radiographic union at 3 months.³²⁻³⁵

For definitive fracture fixation we chose intramedullary fixation. Interlocking humeral nails allow for fixation of segmental or severely comminuted fractures. Union rates with these devices are in the 92 to 100% range, with an average time of healing between 6 and 13 weeks.^{18,19,32}

Our goals in treatment of this particular case were to prevent infection, achieve bone union in good alignment, and restore the limb function. A continuous course of antibiotics is usually indicated in more extensive severe type III open wounds, until a successful wound closure. Multiple irrigation and debridements were repeated at 36- to 48-h intervals until a clean, completely viable wound was present. Our early autogenous bone graft did not prove detrimental, although one may suppose its failure on placement into a host bed that was still in a highly inflammatory state. In severe type III open fractures, or in wounds that are marginal, it may be best to delay cancellous bone grafting until soft tissue has stabilized from an acute trauma, after the risk of infection has been minimized and the early inflammatory stages are passed. Definitive soft tissue coverage, however, should be performed as soon as possible.

CONCLUSION

An adequate debridement is the key to open fracture management. Stabilization in this case was obtained by initial external fixation followed by unreamed nailing. The common denominator for success in these cases is early coverage of vital structures (nerve, vessel, and bone). Type IIIB injuries by definition defy the ability to be closed primarily. If early coverage of vital structures is not possible, local or remote flap coverage may be necessary. With severe injuries, including specific indications such as a dysvascular limb or uncontrolled infection, consideration must be directed to the possibility of early

amputation, rather than to a series of unsuccessful reconstructive procedures.

ACKNOWLEDGMENTS

We thank Vera Srsan Zivanovic (Department of General Surgery and Traumatology, General Hospital Varazdin). The source of all funding for the study has been obtained by the National Health Insurance. No benefits in any form have been received or will be received from a commercial party related directly or indirectly to the subject of this article. Dr. Egol receives research support from Stryker, Synthes and Biomet.

REFERENCES

- Court-Brown CM, Rimmer S, Prakash U, McQueen MM: The epidemiology of open long bone fractures. *Injury* 1998; 29: 529-34.
- Mandrella B, Abebaw TH, Hersi ON: Defect fractures of the upper arm and their treatment in difficult circumstances. 3 case reports from Ethiopian and Somalian provincial hospitals. *Unfallchirurg* 1997; 100: 154-8.
- Norman D, Hamoud K, Ries D, et al: External humeral fixation in war injuries. *Harefuah* 1996; 131: 310-2, 375.
- Sarmiento A, Waddell JP, Latta LL: Diaphyseal humeral fractures: treatment options. *Instr Course Lect* 2002; 51: 257-69.
- Tu Y, Yen C, Ma C, et al: Soft-tissue injury management and flap reconstruction for mangled lower extremities. *Injury* 2008; 39: 75-95.
- Rowley DI: The management of war wounds involving bone. *J Bone Joint Surg Br* 1996; 78: 706-9.
- Wisniewski TF, Radziejowski MJ: Gunshot Fractures of the Humeral Shaft Treated with External Fixation. *J Orthop Trauma* 1996; 10: 273-8.
- Geissler WB, Teasedall RD, Tomasin JD, et al: Management of low velocity gunshot-induced fractures. *J Orthop Trauma* 1990; 4: 39-41.
- Gustilo RB, Mendoza RM, Williams DN: Problems in the management of type III (severe) open fractures: a new classification of type III open fractures. *J Trauma* 1984; 24: 742-6.
- Park HJ, Uchino M, Nakamura K, et al: Immediate interlocking nailing versus external fixation followed by delayed interlocking nailing for Gustilo type IIIB open tibial fractures. *J Orthop Surg* 2007; 15: 131-6.
- Stewart MP, Kinninmonth A: Shotgun wounds of the limbs. *Injury* 1993; 24: 667.
- Coupland RM: The Red Cross classification of war wounds: the E.X.C.F.V.M. scoring system. *World J Surg* 1992; 16: 910-7.
- Togawa S, Yamami N, Nakayama H, et al: The validity of the mangled extremity severity score in the assessment of upper limb injuries. *J Bone Joint Surg Br* 2005; 87: 1516-9.
- Kirkup J: *A History Of Limb Amputation*. London, UK, Springer, 2007.
- Holtom PD: Antibiotic prophylaxis: current recommendations. *J Bone Joint Surg Br* 2006; 14: 98-100.
- Knapp TP, Patzakis MJ, Lee J, Seipel PR, Abdollahi K, Reisch RB: Comparison of intravenous and oral antibiotic therapy in the treatment of fractures caused by low-velocity gunshots. A prospective, randomized study of infection rates. *J Bone Joint Surg Am*. 1996; 78: 1167-71.
- Elstrom JA, Pankovich AM, Egwele R: Extra-articular low-velocity gunshot fractures of the radius and ulna. *J Bone Joint Surg Am* 1978; 60: 335-41.
- Zinman C, Norman D, Hamoud K, Reis ND: External fixation for severe open fractures of the humerus caused by missiles. *J Orthop Trauma* 1997; 11: 536-9.
- Atalar AC, Kocaoglu M, Demirhan M, Bilsel K, Eralp L: Comparison of three different treatment modalities in the management of humeral shaft nonunions (plates, unilateral, and circular external fixators). *J Orthop Trauma* 2008; 22: 248-57.
- Mahoney PF, Ryan JM, Brooks AJ, Schwab CW: *Clinical Ballistics: Surgical Management of Soft-Tissue Injuries—General Principles*. London, UK, Springer, 2005.
- Bender JS, Hoekstra SM, Levison MA: Improving outcome from extremity shotgun injury. *Am Surg* 1993; 59: 359-64.
- Bhandari M, Schemitsch EH, Adili A, et al: High and low pressure pulsatile lavage of contaminated tibial fractures: an in vitro study of bacterial adherence and bone damage. *J Orthop Trauma* 1999; 13: 526-33.
- Keating JF, Blachut PA, O'Brien PJ, et al: Reamed nailing of open tibial fractures: Does the antibiotic bead pouch reduce the infection rate? *J Orthop Trauma* 1996; 10: 298-303.
- Herscovici D Jr, Sanders RW, Scaduto JM, et al: Vacuum-assisted wound closure (VAC therapy) for the management of patients with high-energy soft tissue injuries. *J Orthop Trauma* 2003; 17: 683-8.
- Bowyer GW, Rossiter ND: Management of gunshot wounds of the limbs. *J Bone Joint Surg Br* 1997; 79: 1031-6.
- Levin LS: Early versus delayed closure of open fractures. *Injury* 2007; 38: 896-9.
- Delong WG Jr, Born CT, Wei SY, et al: Aggressive treatment of 119 open fracture wounds. *J Trauma* 1999; 46: 1049-54.
- Godina M: Early microsurgical reconstruction of complex trauma of the extremities. *Plast Reconstr Surg* 1986; 78: 285-92.
- Gopal S, Majumder S, Batchelor AG, et al: Fix and flap: the radical orthopaedic and plastic treatment of severe open fractures of the tibia. *J Bone Joint Surg Br* 2000; 82: 959-66.
- Ordog GJ, Sheppard GF, Wasserberger JS, et al: Infection in minor gunshot wounds. *J Trauma* 1993; 34: 358-65.
- Deitch EA, Grimes WR: Experience with 112 shotgun wounds of the extremities. *J Trauma* 1984; 24: 600-3.
- Karas EH, Strauss E, Sohail S: Surgical stabilization of humeral shaft fractures due to gunshot wounds. *Orthop Clin North Am* 1995; 26: 65-73.
- Dwyer AJ, Patnaik S, Smibert JG: Case report: nonunion of complex proximal humerus fractures treated with locking plate. *Injury* 2007; 38: 409-13.
- Dicpinigaitis PA, Koval KJ, Tejwani NC, et al: Gunshot wounds to the extremities. *Bull NYU Hosp Jt Dis* 2006; 64: 139-55.
- Wiss DA, Gellman H: Gunshot wounds to the musculoskeletal system. In: *Skeletal Trauma*, p 37. Edited by Browner BD, Jupiter JB, Levine AM, et al. Philadelphia, PA, WB Saunders, 1992.

Copyright of Military Medicine is the property of Association of Military Surgeons of the United States and its content may not be copied or emailed to multiple sites or posted to a listserv without the copyright holder's express written permission. However, users may print, download, or email articles for individual use.